TOD 46.ULUSAL KONGRE, Kurs, EKİM 2011, Kıbrıs

VİTREORETİNAL CERRAHİ TEMEL TEKNİKLER

DR. ŞENGÜL ÖZDEK
GAZİ GÖZ

BAŞLARKEN

- Vitreoretinal Cerrahi şablonu olan bir cerrahi değil
- Genel kurallar
- Geçerli doğrular
- Cerraha özgü yöntemler
- Yaratıcı çözümler

1. Adım: Girişler

- Transkonjonktival trokarlar
  - 20G, 23G, 25G
- Konjonktiva açılması, sklerotomiler

Transkonjonktival trokarlar

- Tek adım / 2 adımda
- Video

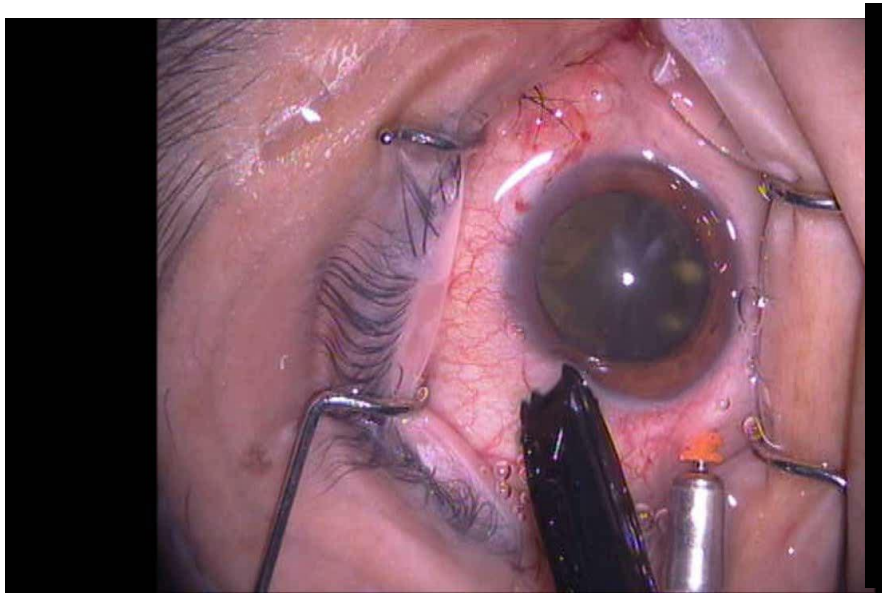

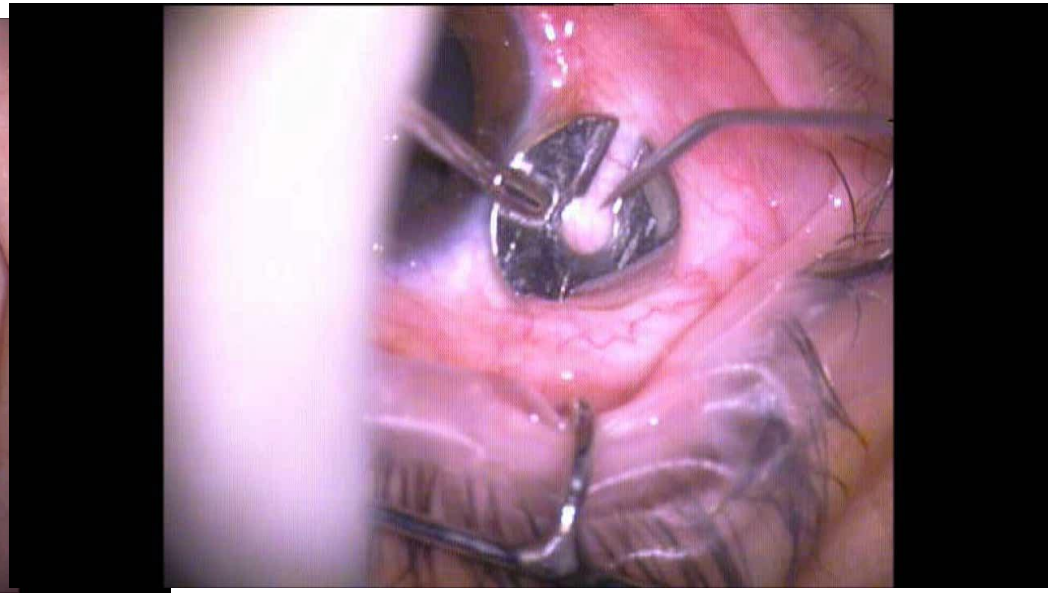

Konjonktiva açılması, Sklerotomiler

- Peritomi: giriş yerlerinden 3 bölge
- Alt/Üst Temporal ve ÜN (2 peritomi)
  - İlk cerrahi
  - Vitreoretinal cerrahiler geçirmiş göz
  - Trabekülektomili göz, Glokomlu göz
  - Skleral Fix IOL olan göz

Peritomi

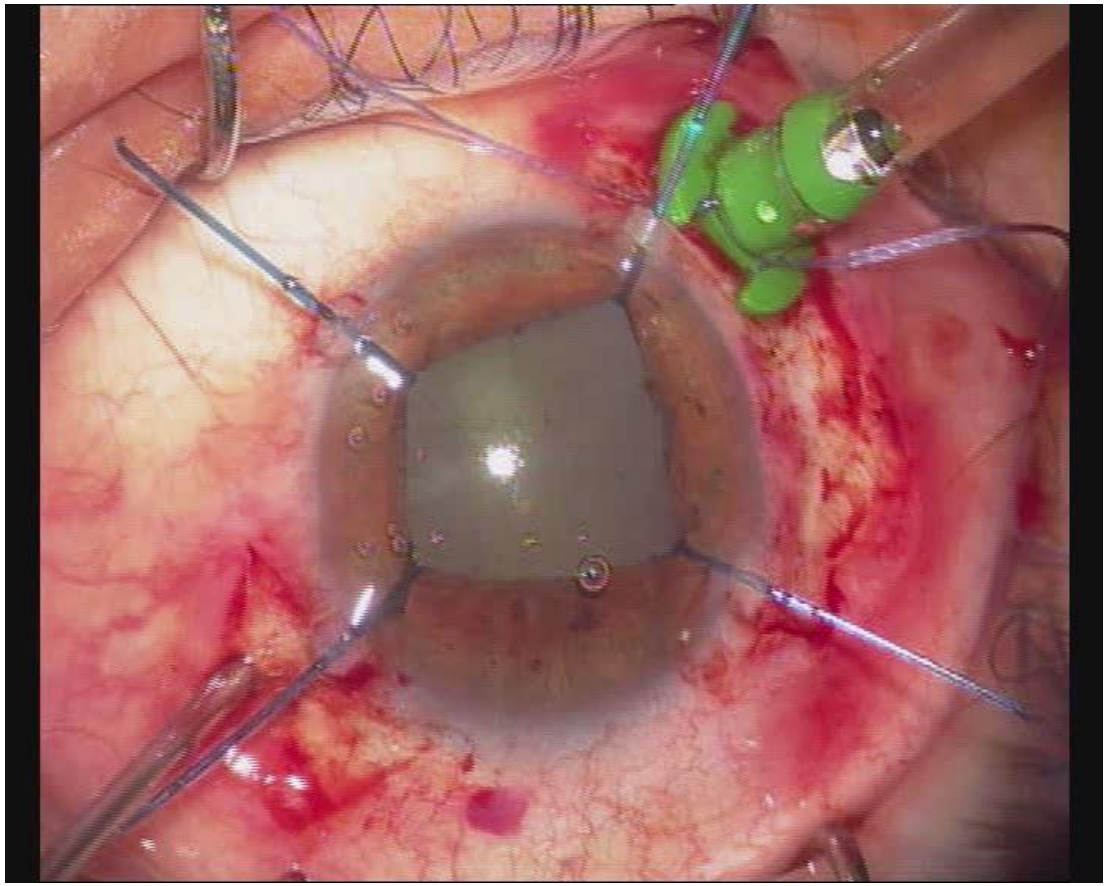

Trab op gözde RD

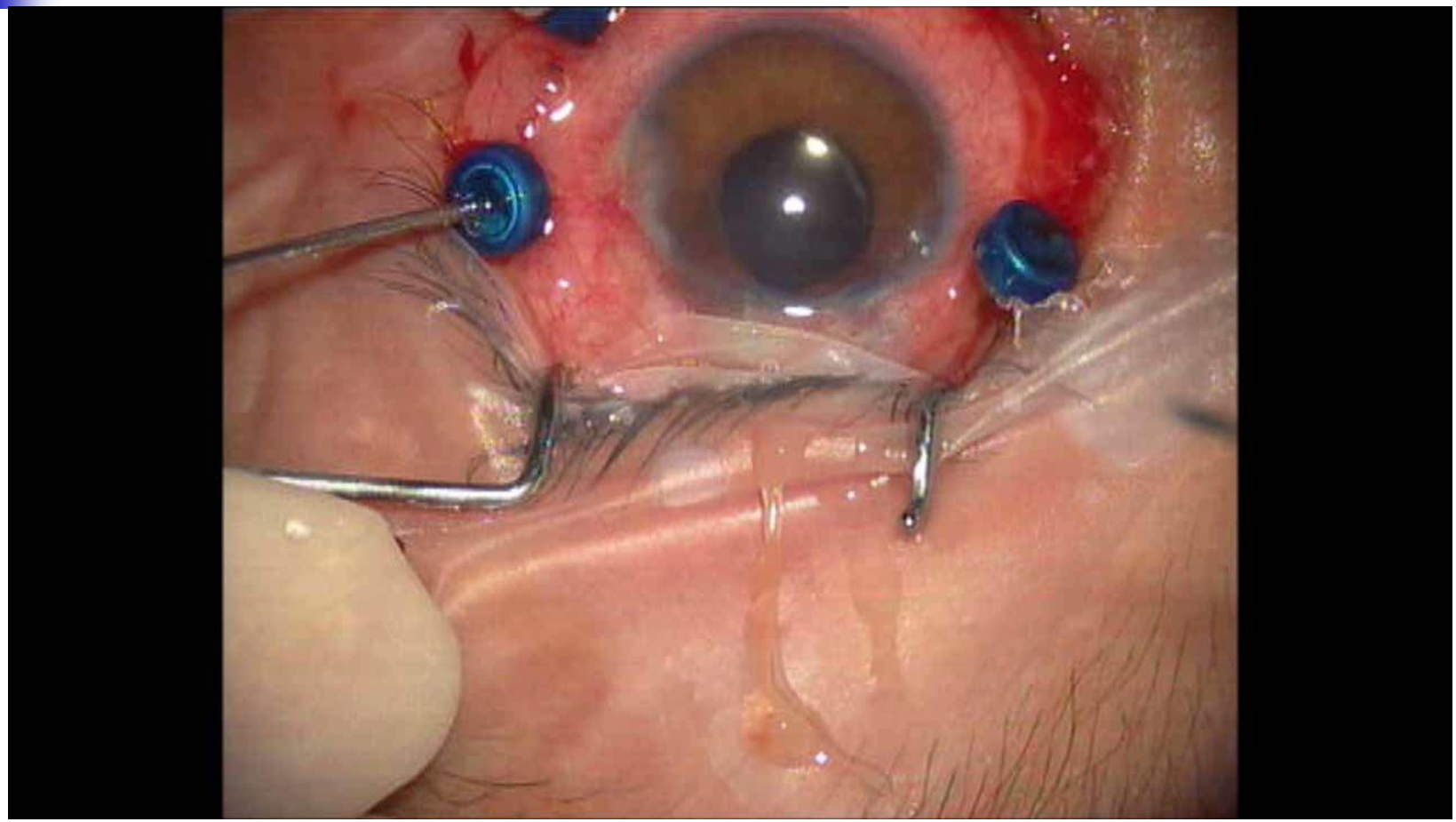

İnfüzyon kanülü seçimi

- Silikon verme ihtimali varsa yüksek viskositeye uygun olmalı
- 6mm kanül:
  - Koroid efüzyonu varlığı,
  - Psödodofak/Afak veya Kat cerrahisi kombine edilecekse (4-6mm)

İnfüzyon kanülü yerleşimi

- AT kadran
- Limbustan 3mm veya 3.5mm (fakik)

Matress sütür (U şeklinde)

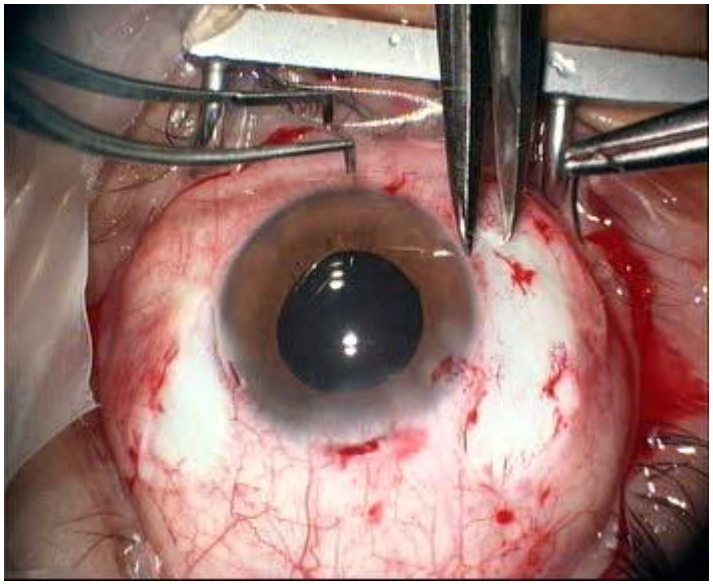

Çapraz sütür (X şeklinde)

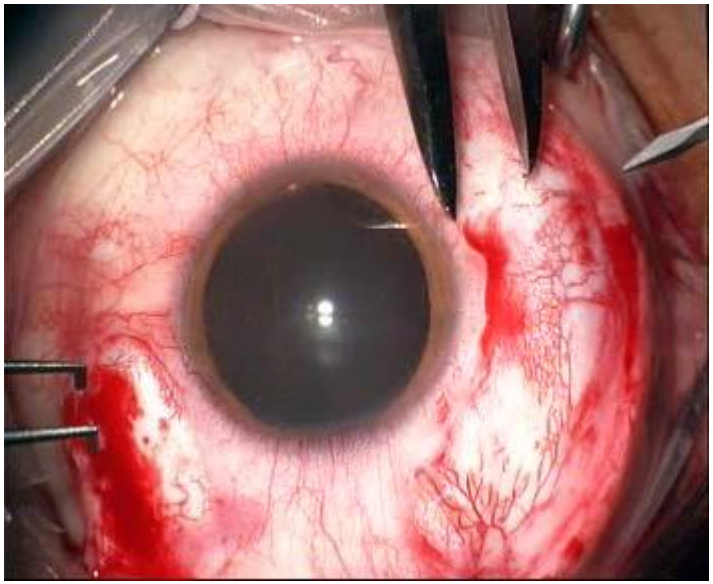

Dr. L. Karabaş'ın arşivinden

İnfüzyon kanülünde sorunlar

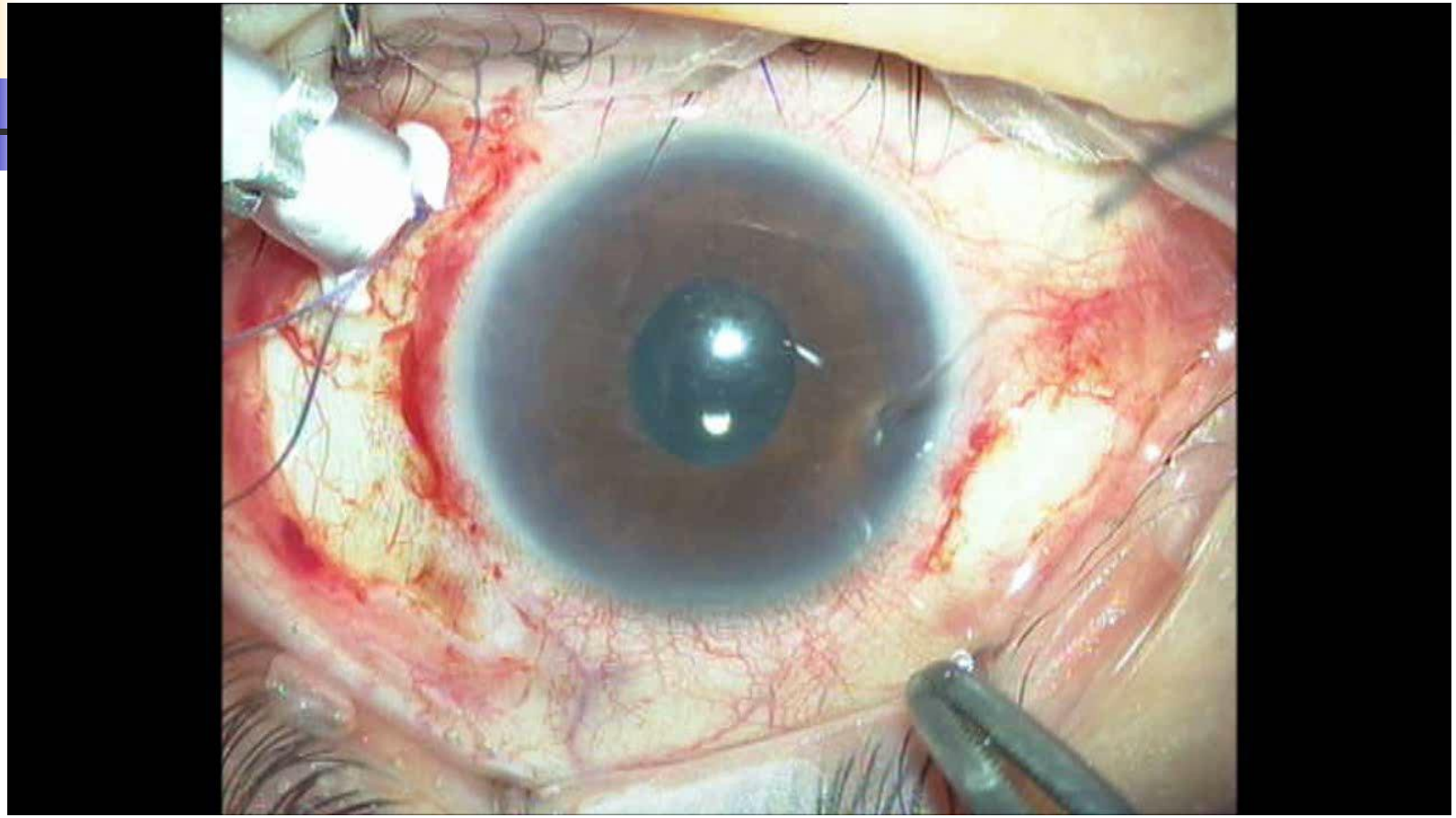

- Kanülün uygun şekilde sabitlenmesi
- Subretinal-koroid altı infüzyon

Diğer sklerotomiler

- 150 – 160 derece aralıklı
- 3 – 9 aksından kaçınmalı
- Çok önde (lense değebilir) veya arkada kalmamalı (vitreus-retina inkarserasyonu!)

Vitrektomi: Genel prensip

- Arkadan öne
- Merkezden perifere
  - Core vitrektomi
  - Arka hyaloid
  - Periferik vitreus
  - Vitreus tabanı

Santral (core) Vitrektomi

- Santral vitreus, lens arkası, giriş yerleri etrafı
- Nisbeten yüksek vakum / düşük hız kullanılabilir (daha kısa sürede tamamlanır)

Arka hyaloid ayrılması

- Pik, Okütom,Triamsinolon

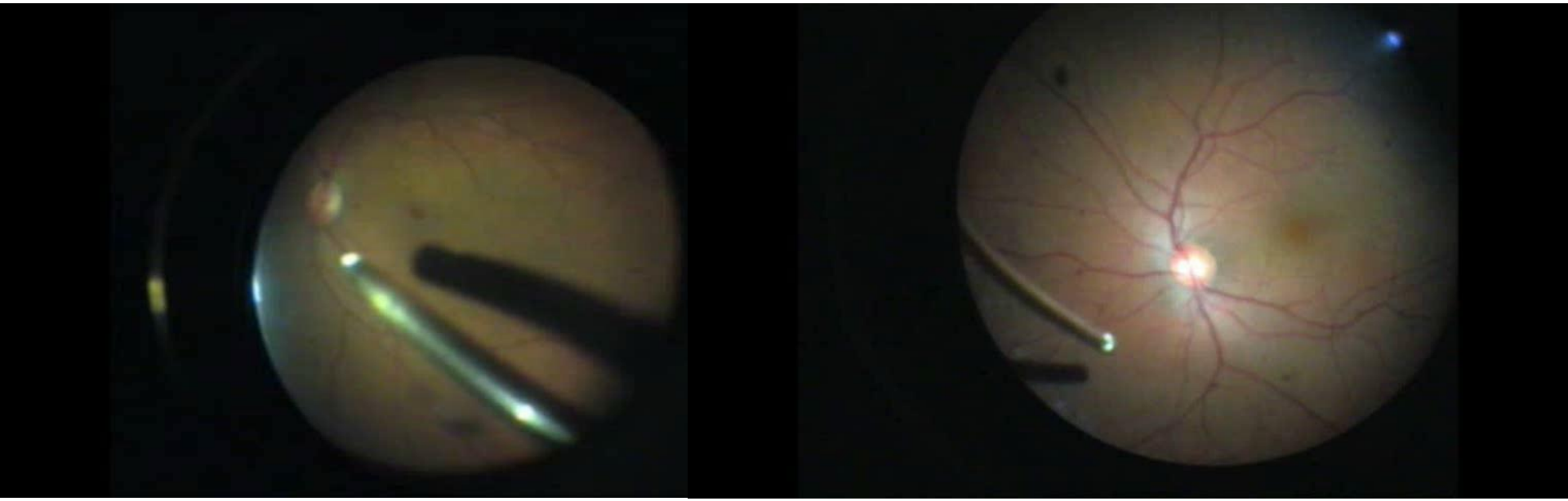

Periferik Vitrektomi

- Yüksek kesi hızı
- Düşük ancak yeterli vakum
- Retinaya doğru-dik yönde
- Çökertme
  - Asistan
  - Avize aydınlatma-cerrah

Periferik vitrektomi

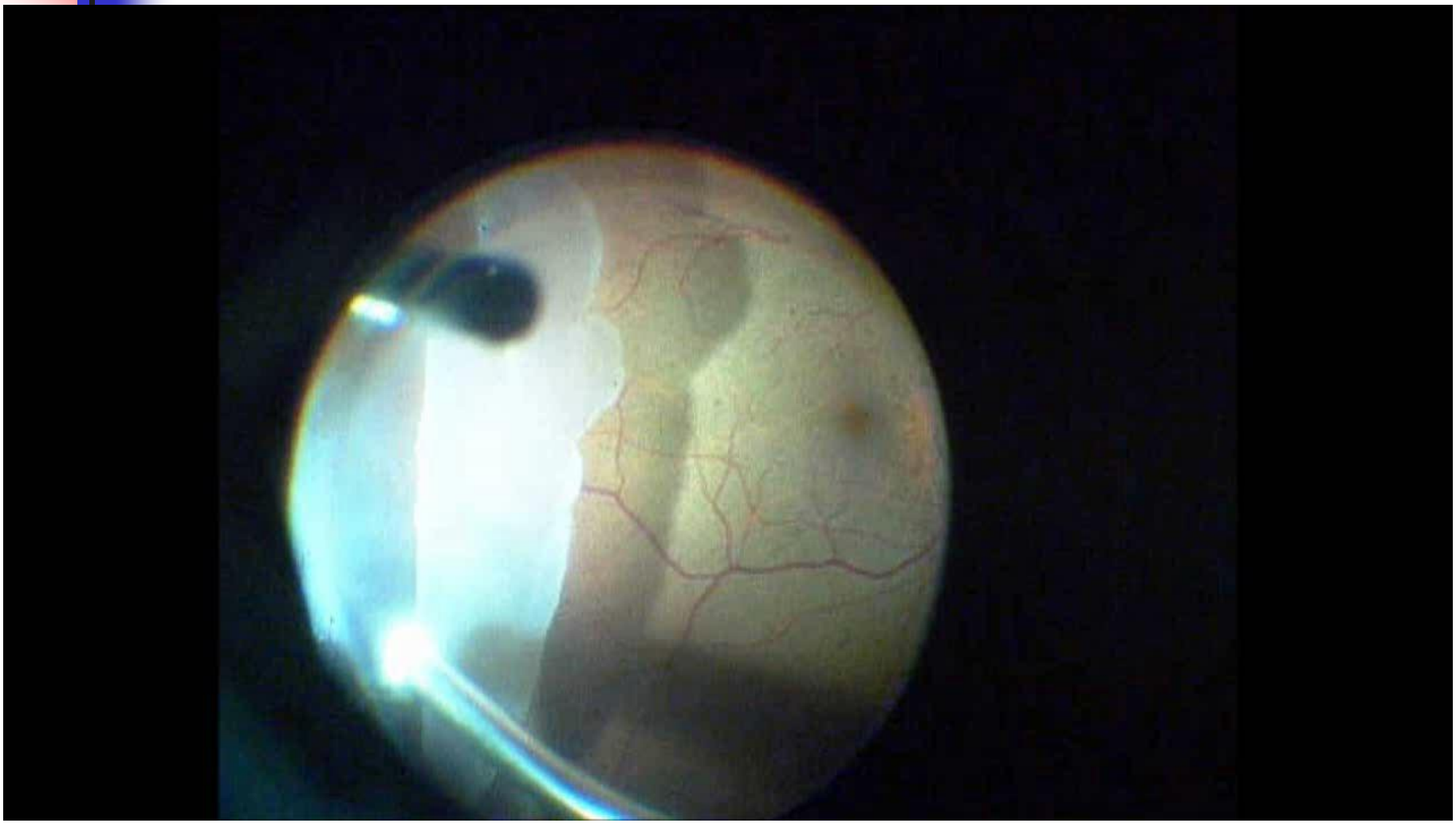

Vitreus tabanı temizliği

- RD, travma: Olmazsa olmaz!
- Maküla cerrahileri: Şart değil

Vitreus tabanı temizliği Çökertme (asistan)

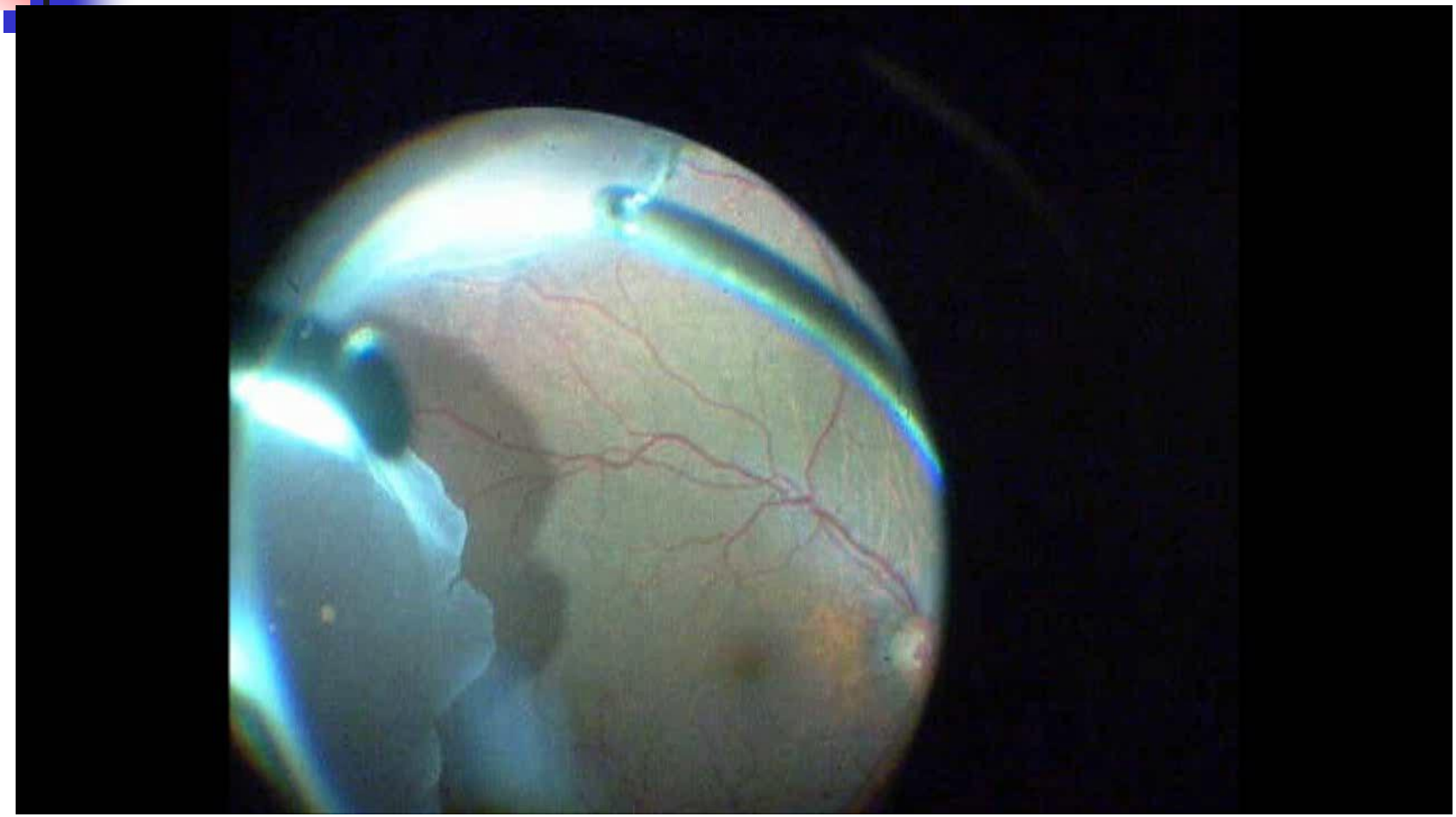

Vitreus tabanı temizliği
Avize ışık- Çökertme (cerrah)

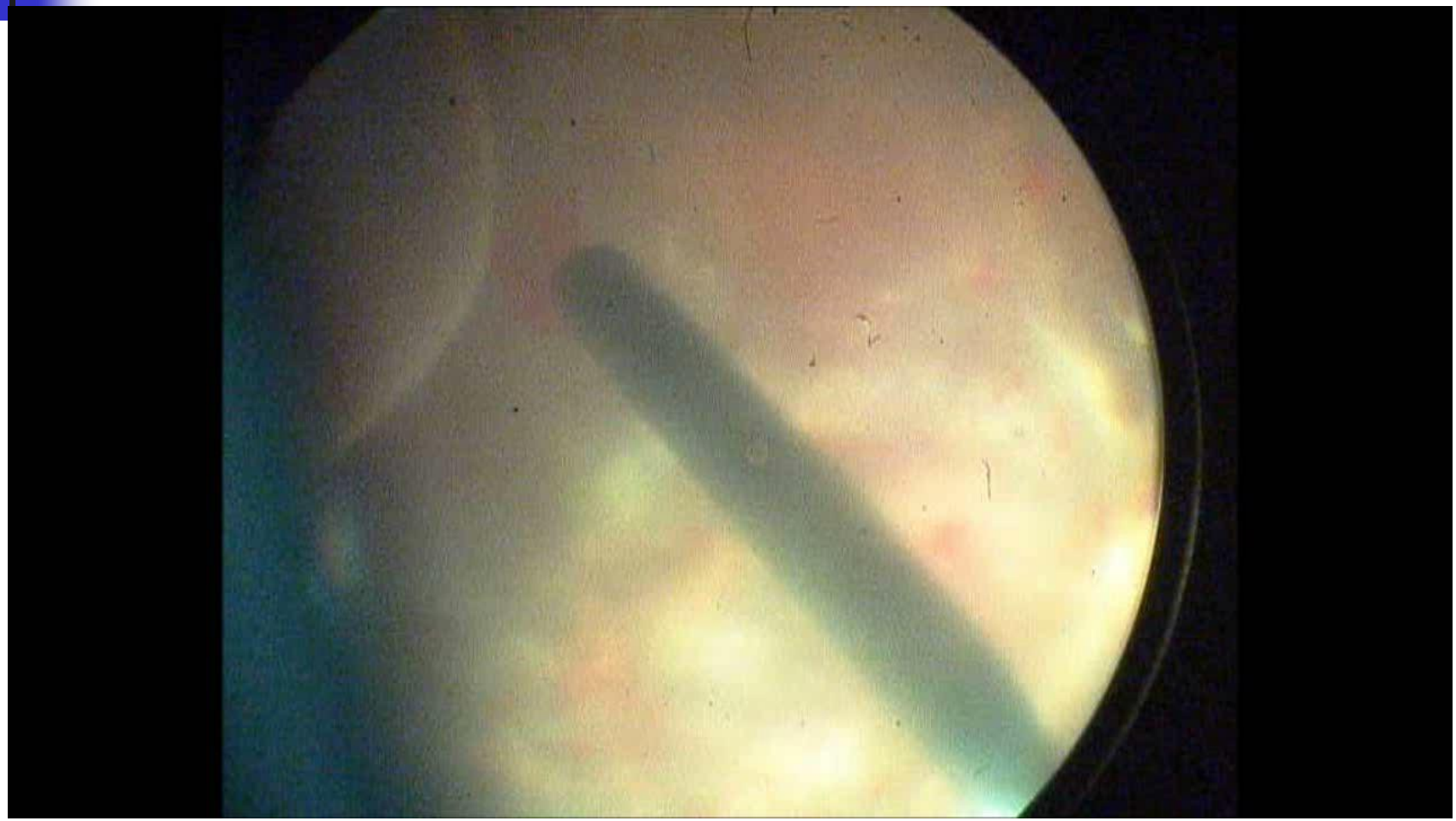

Periferik kontrol - Çökertme

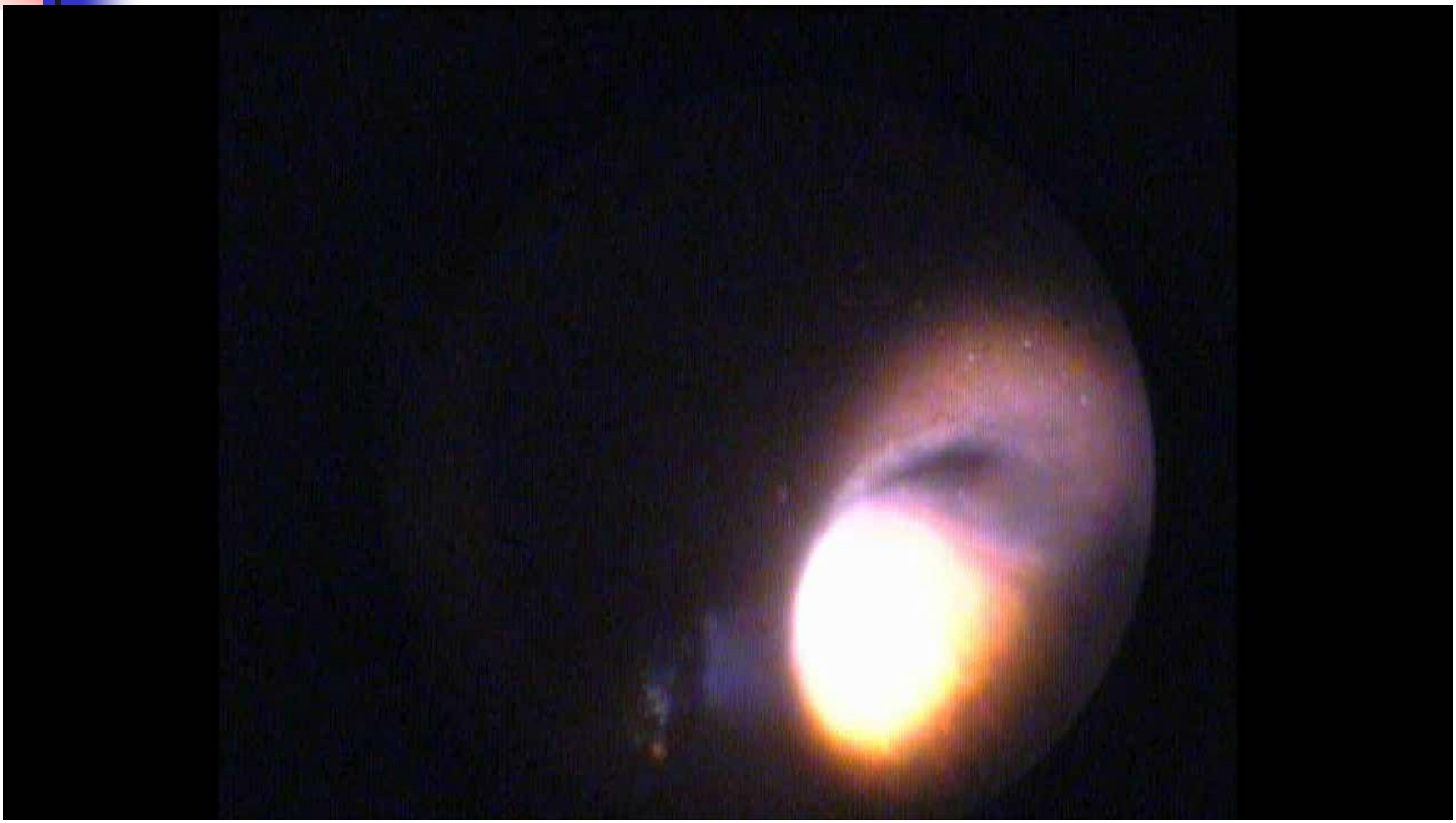

Epiretinal Membran

- Membran soyma
- Segmentasyon
- Delaminasyon

Epiretinal Membran-IVT

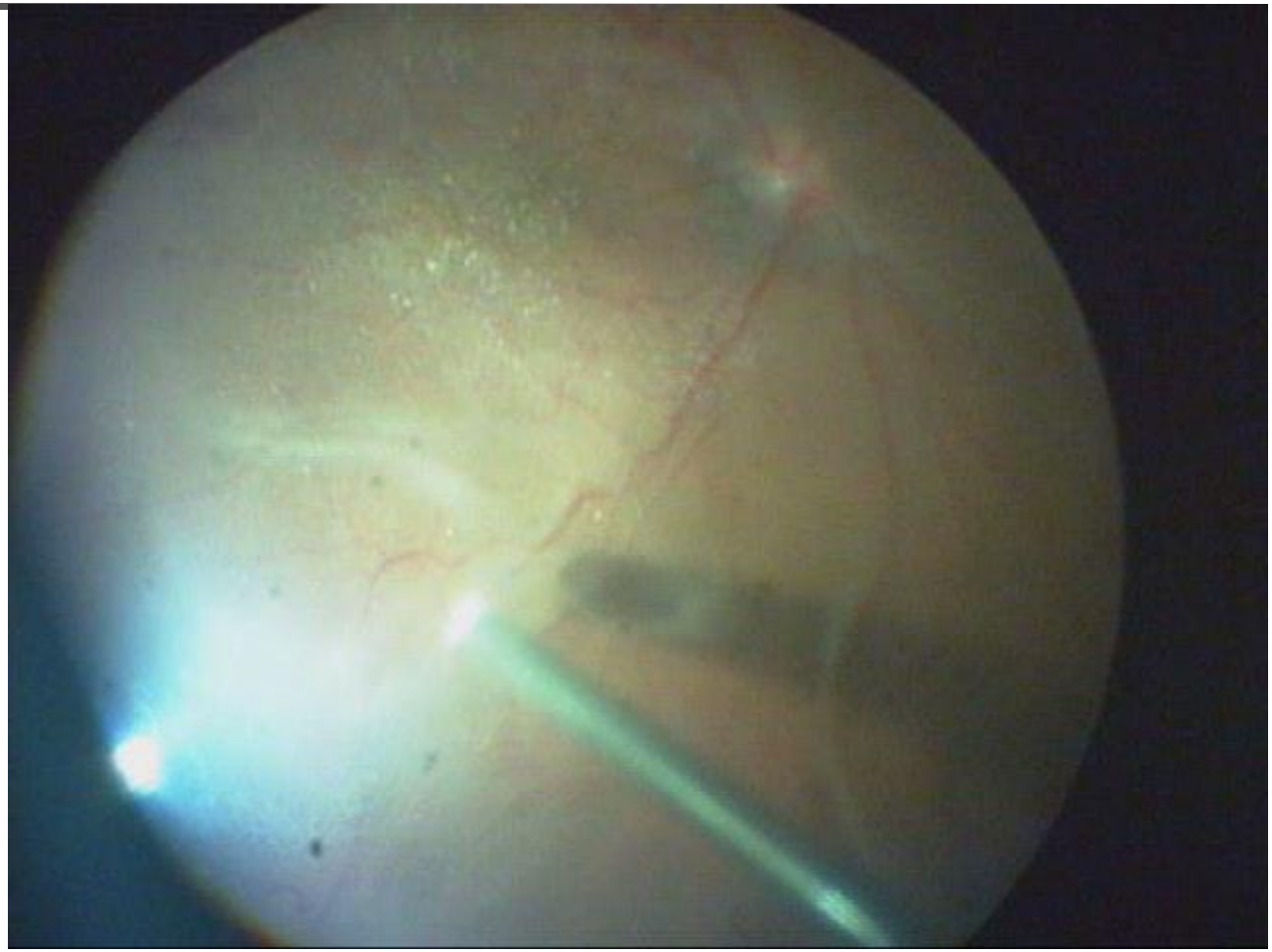

ERM - Delaminasyon (Bimanuel)

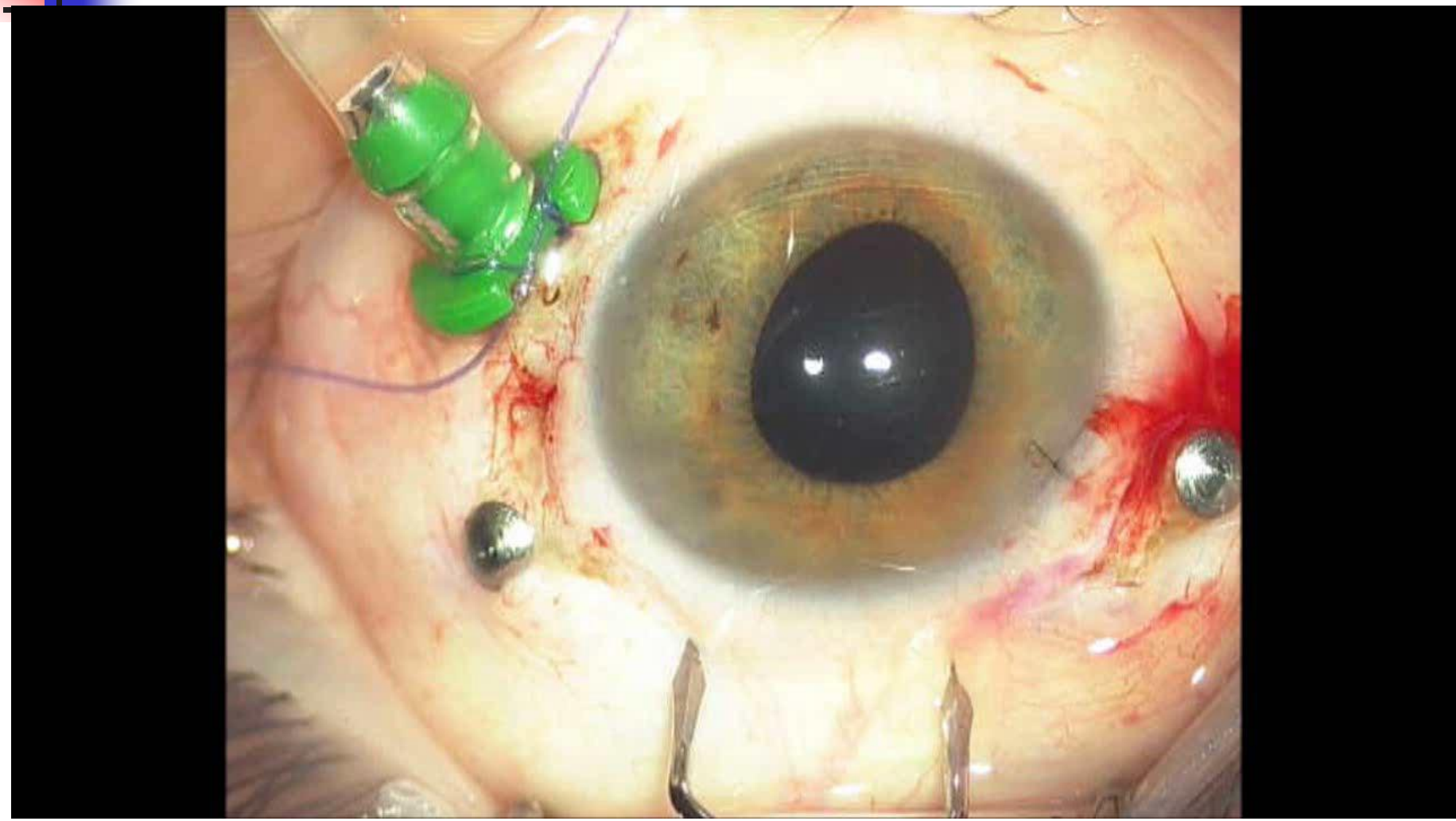

ERM-segmentasyon

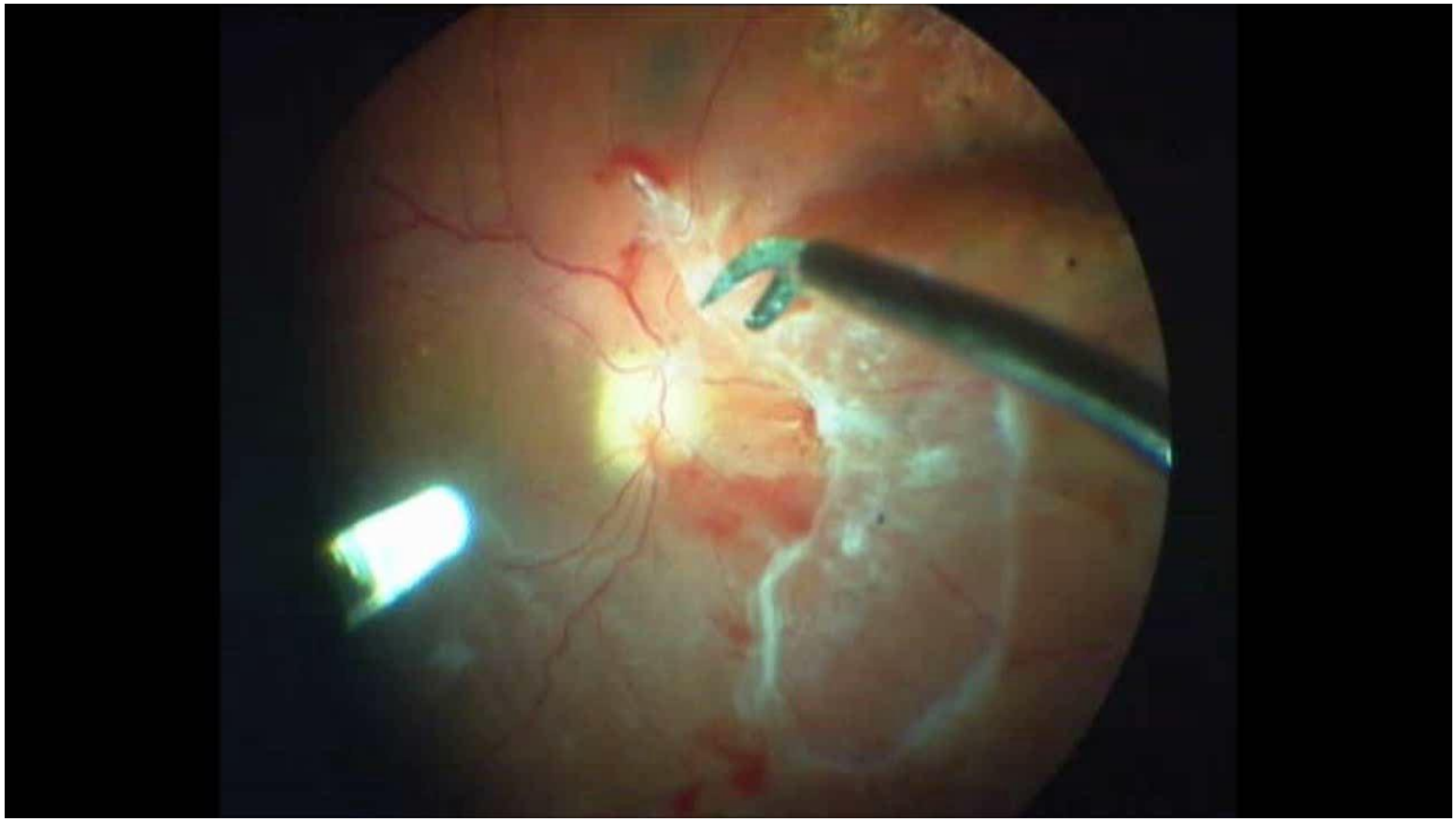

Perop kanama

- Basınç arttırma
- Laser
- Koter
- Direkt temasla bası

Perop kanama - Laser

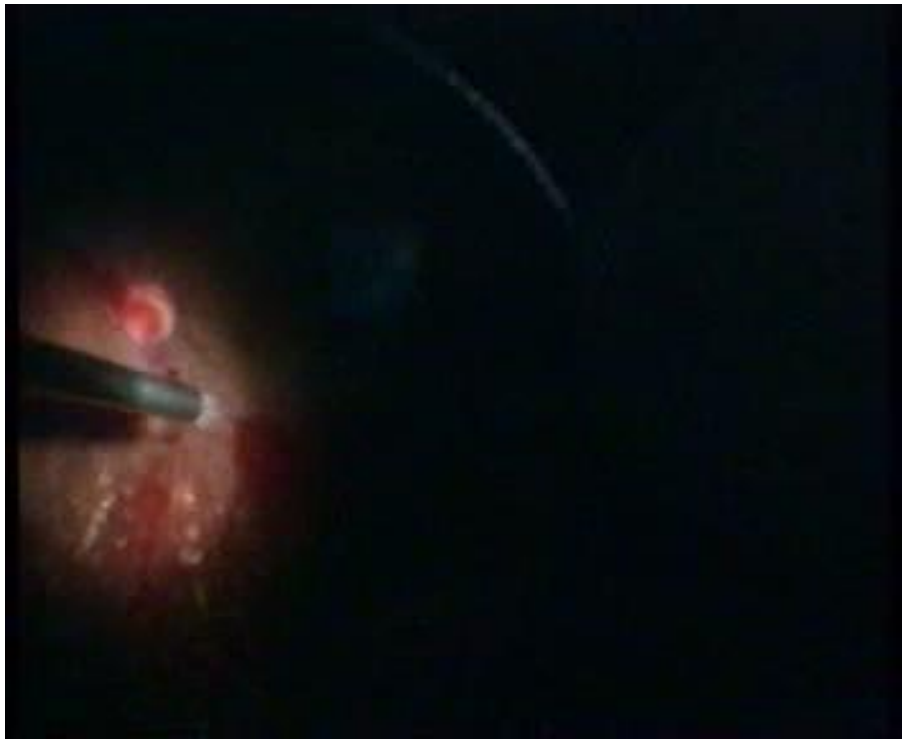

Dr. Levent Karabaş'ın arşivinden

Perop Kanama - Koter

Dr. Levent Karabaş'ın arşivinden

Görüntü sorunları

Küçük pupilla

- Ön kamaraya adrenalin
- Geniş açılı kontakt lens
- İris çengelleri
- Ön kamarayı daraltma
- Hava altında çalışma

Küçük pupilla

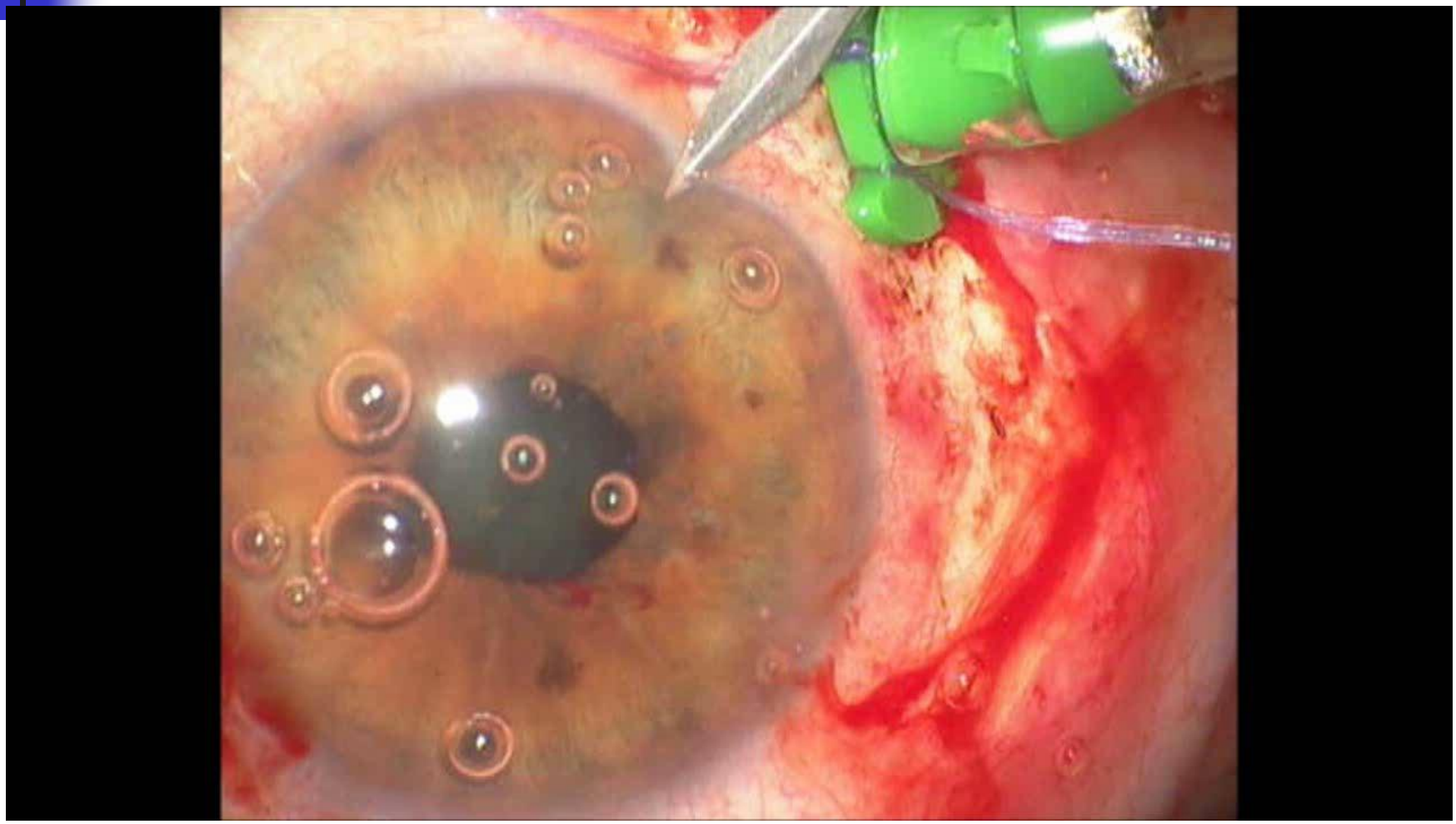

Görüntü sorunları

- Kornea ödemi……..Epiteli kazı
- Descement kırışıklıkları……ÖK VEM
- Ön Kamarada hava-kanama-hipopyon-pigment deşarjı……Temizle
- Katarakt……Lensi al
- IOL arkasında buğu…..VEM

Görüntü sorunları:
Ön kamarada kan-hipopyon

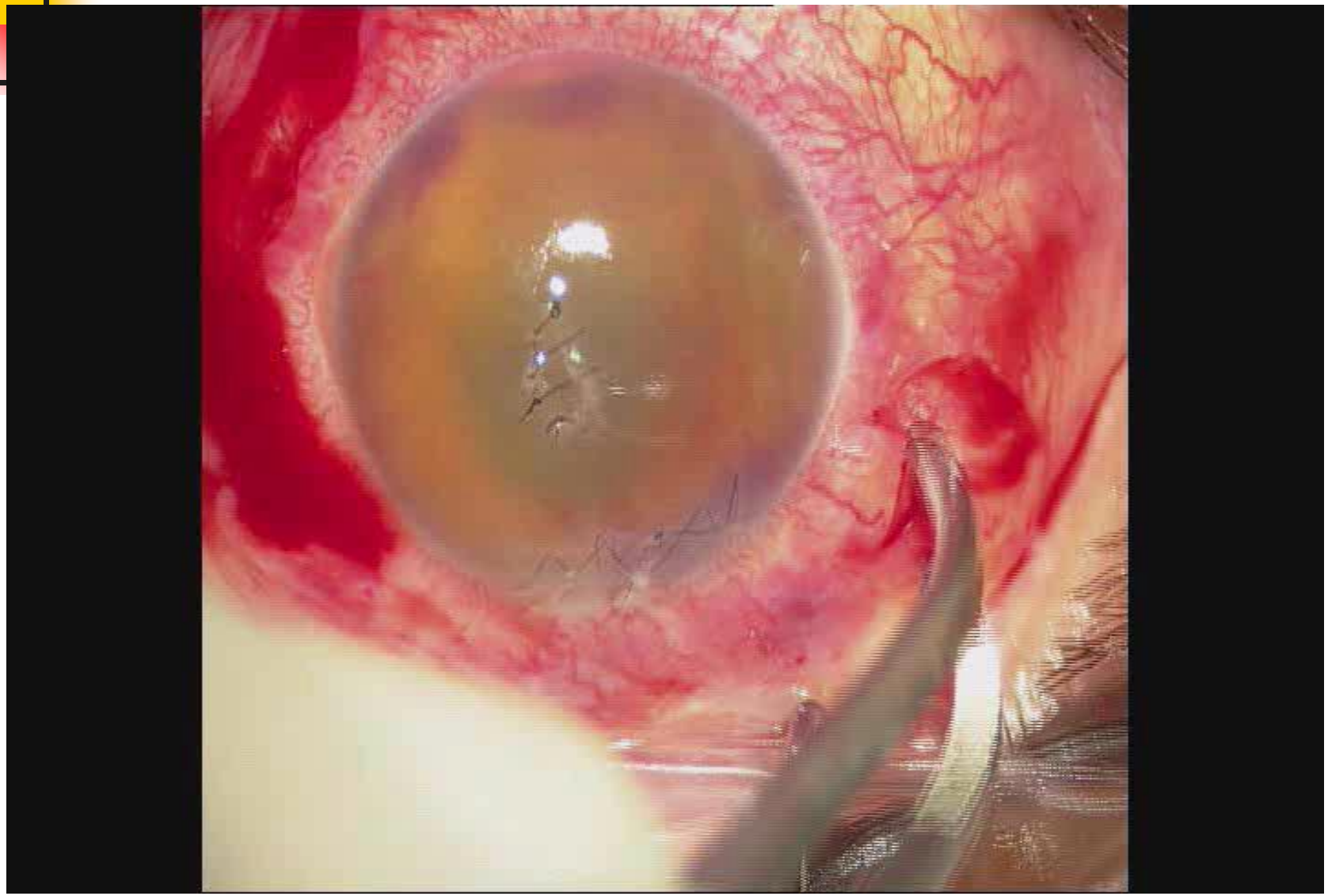

Kornea-lens sorunları

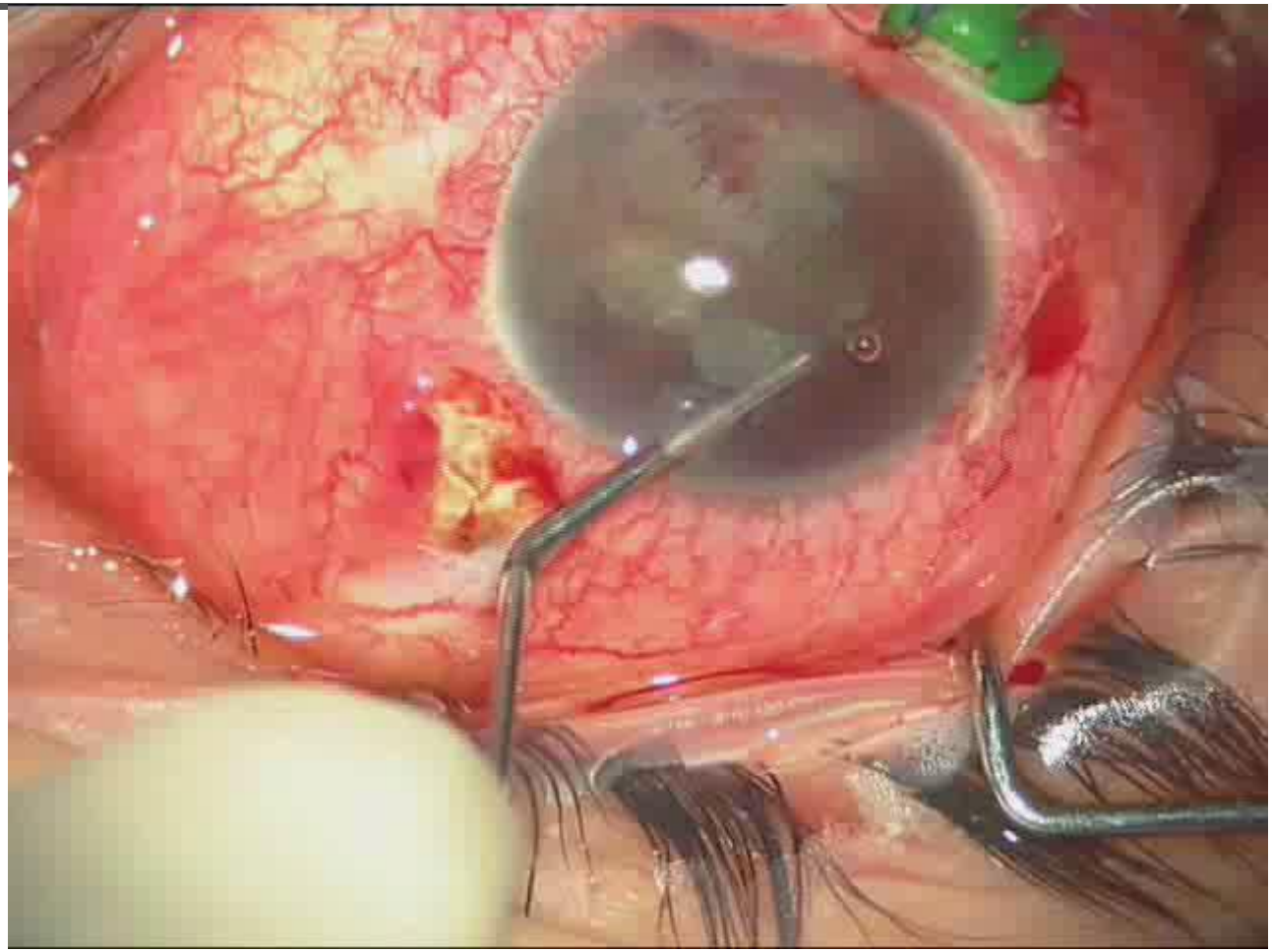

Ön kamarada hava

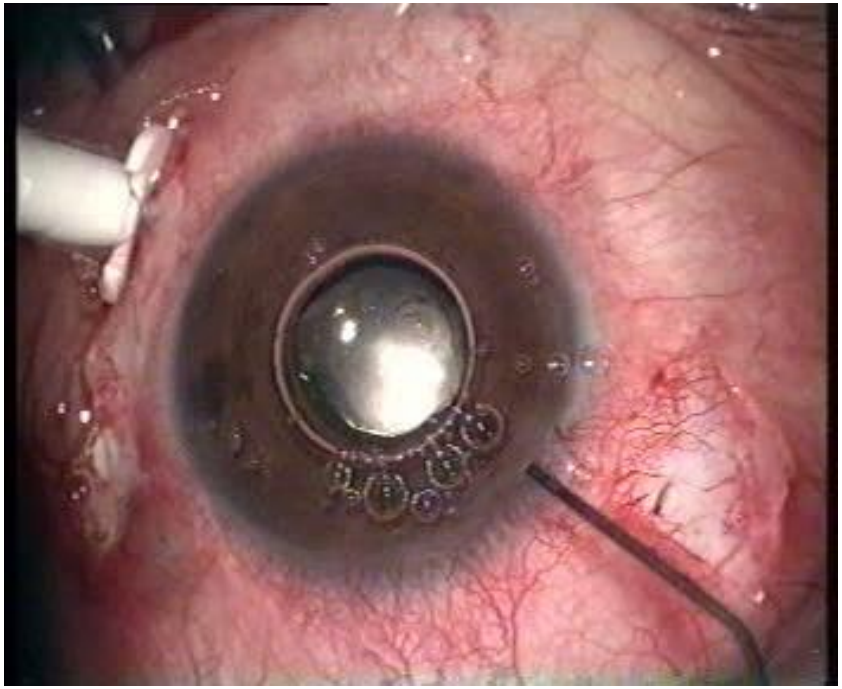

Doç. Dr. L. Karabaş'ın arşivinden

Buğulanma

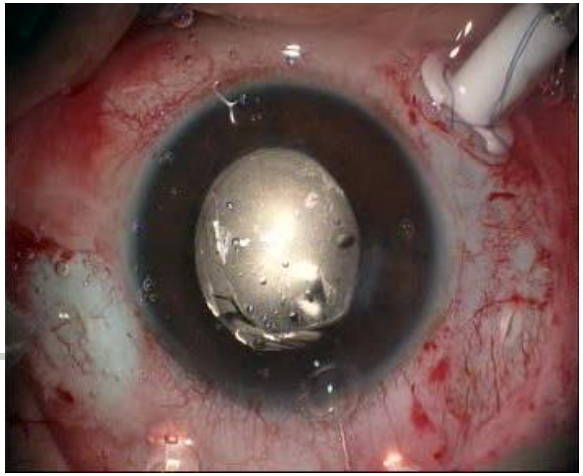

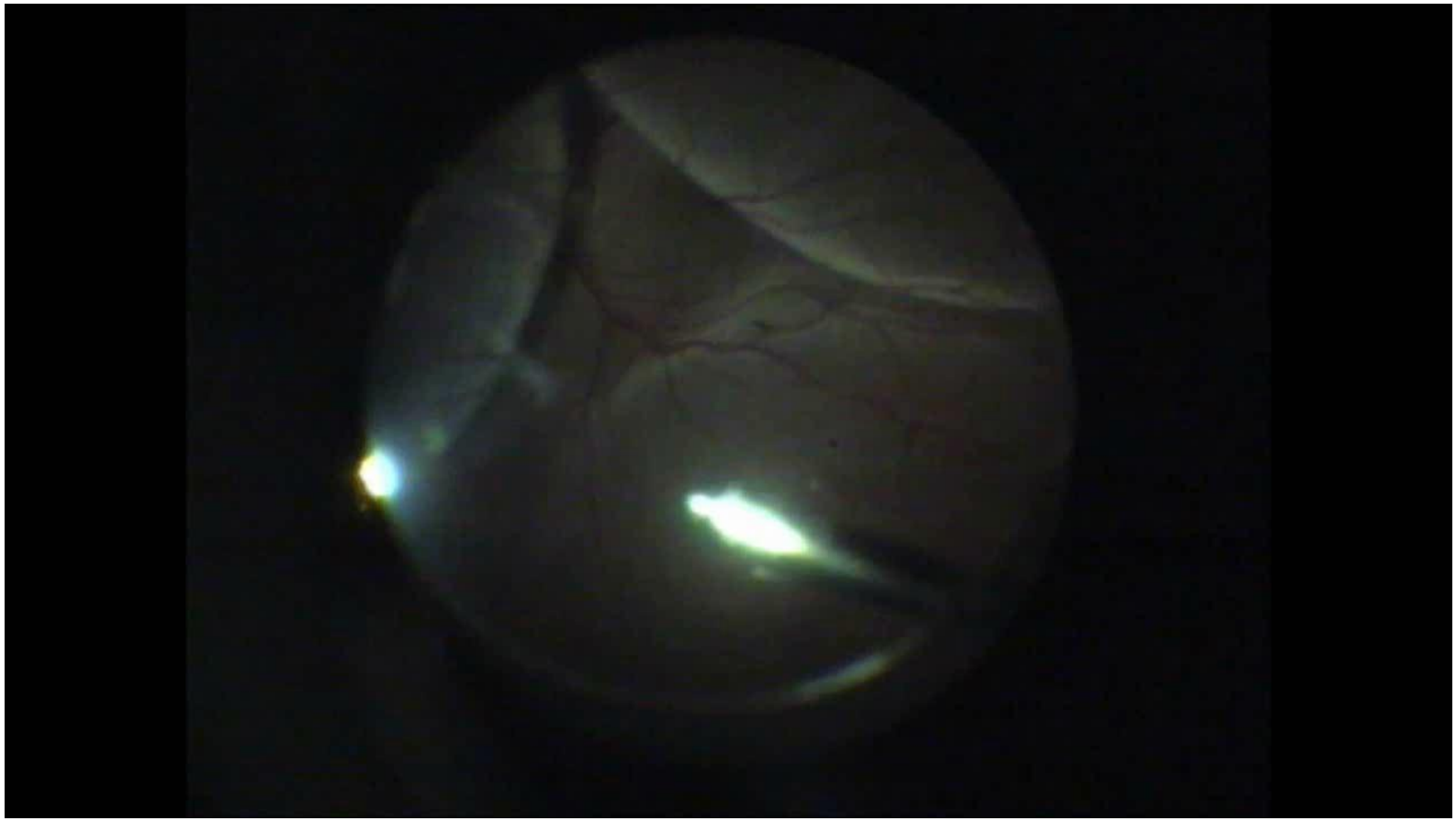

Endotel sorunu-Descemet kırışıklıkları

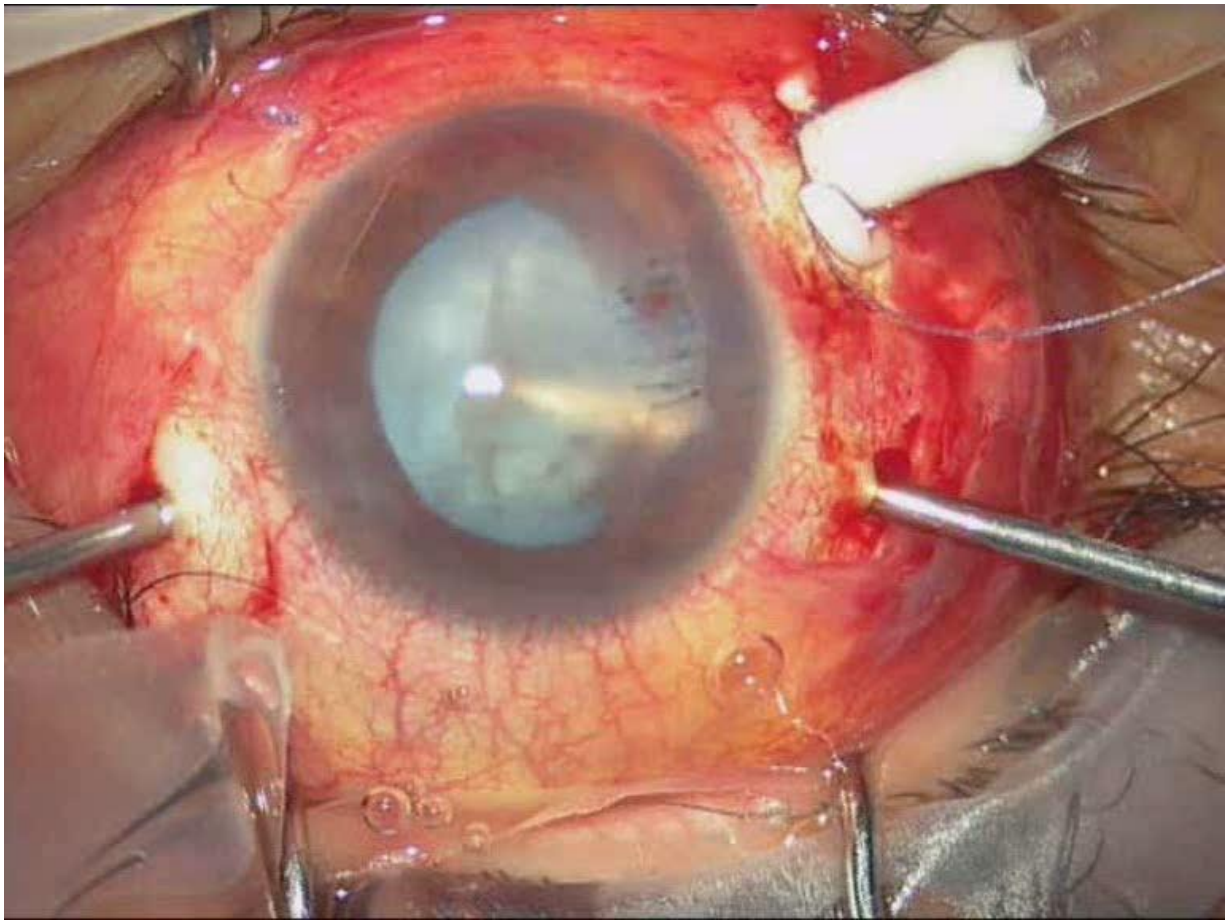

Boya verirken dikkat!

- İnfüzyon sıvısını kapat
- Yavaş enjeksiyon
- Yeterince bekle

Boya verilmesi

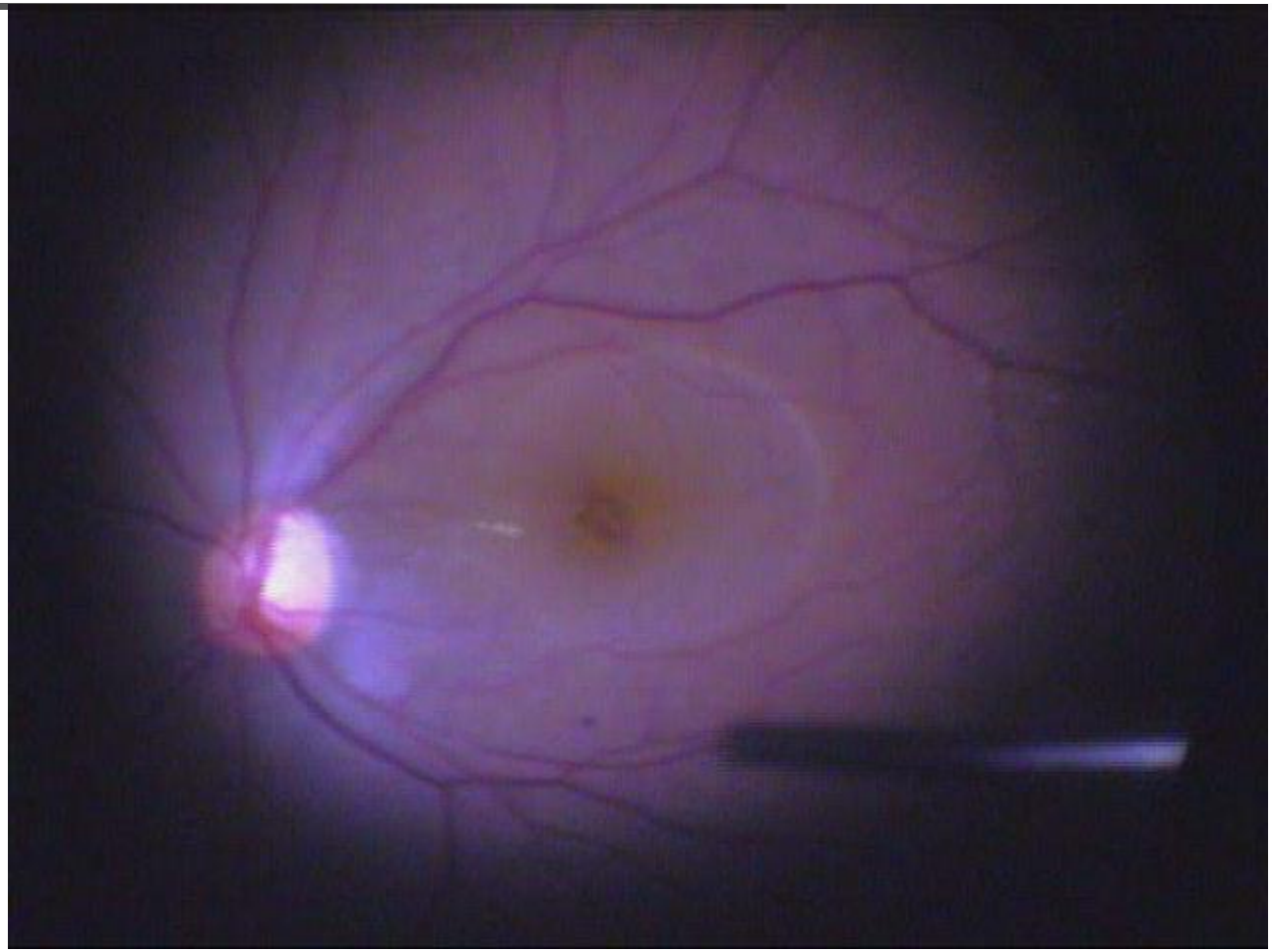

Lazer uygulaması

- Probun retinaya uzaklığı!
- Probun retinaya dik olması
- Subretinal sıvı varlığı!
- Hava altında güç hafif arttırılabilir.
- Self indentasyon ve ışıklı laser probu periferik laser uygulamasını kolaylaştırır.

Laser uygulaması

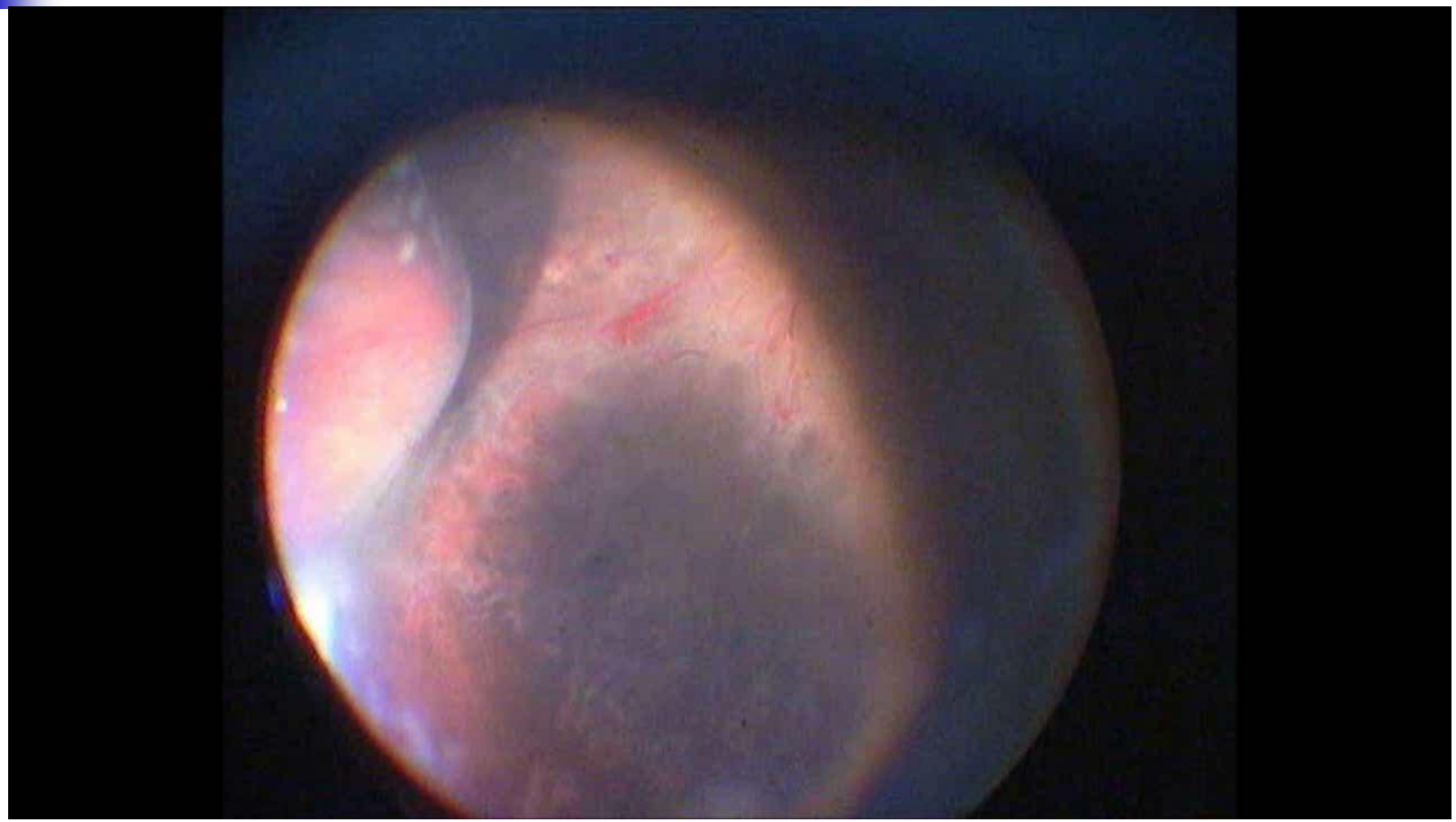

Sıvı-Hava değişimi

- RD: Önce subretinal sıvıyı boşalt!
- PFC varsa önce öndeki BSS'i boşalt!
- Optik şartlara dikkat!

Sıvı-Hava- Gaz değişimi

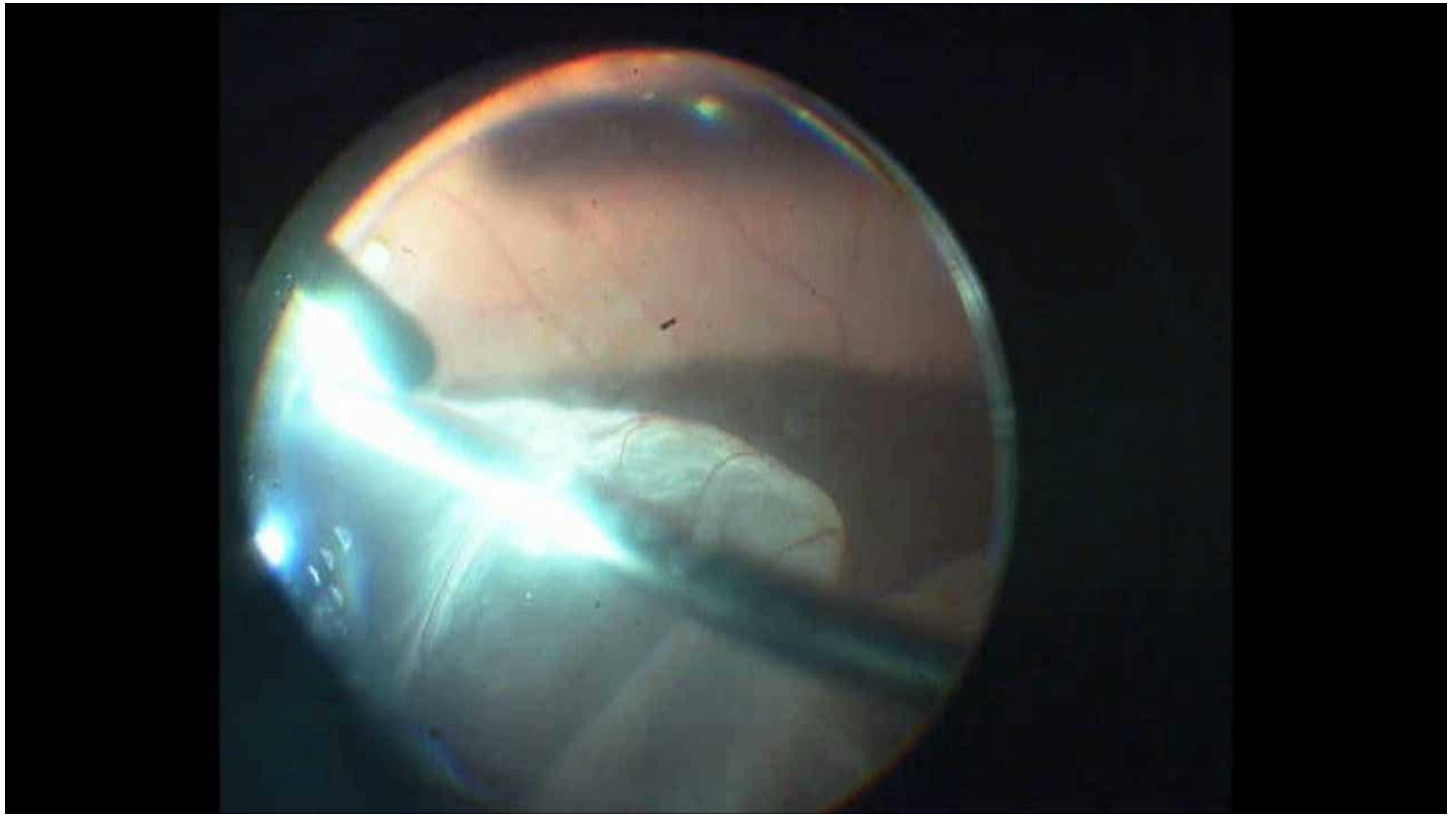

Tamponad –PFC Silikon Değişimi

Ön Kamarada silikon

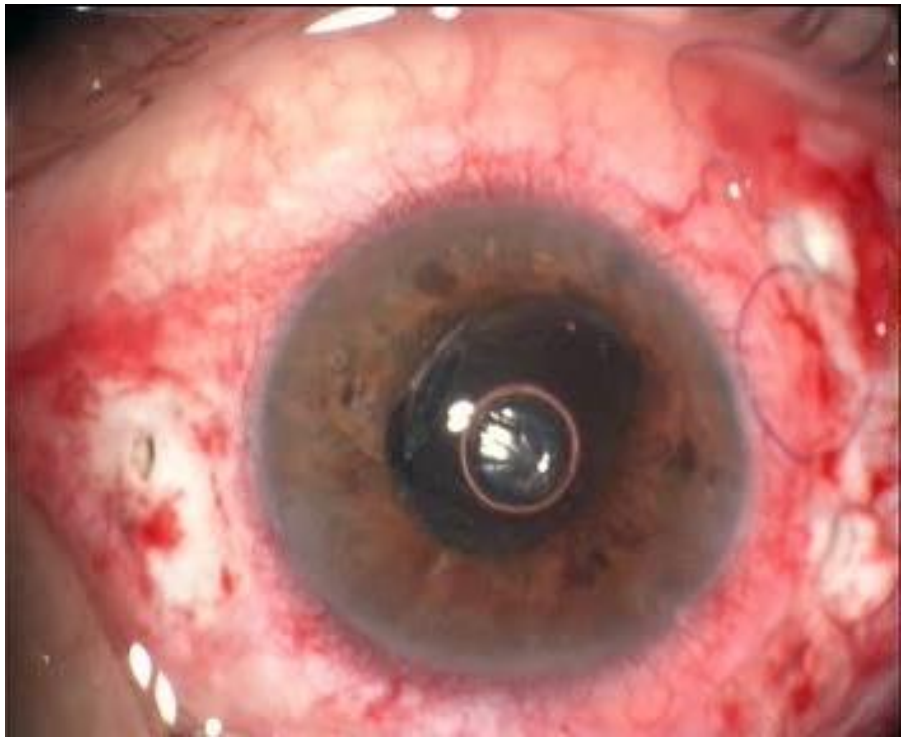

Doç. Dr. L. Karabaş'ın arşivinden
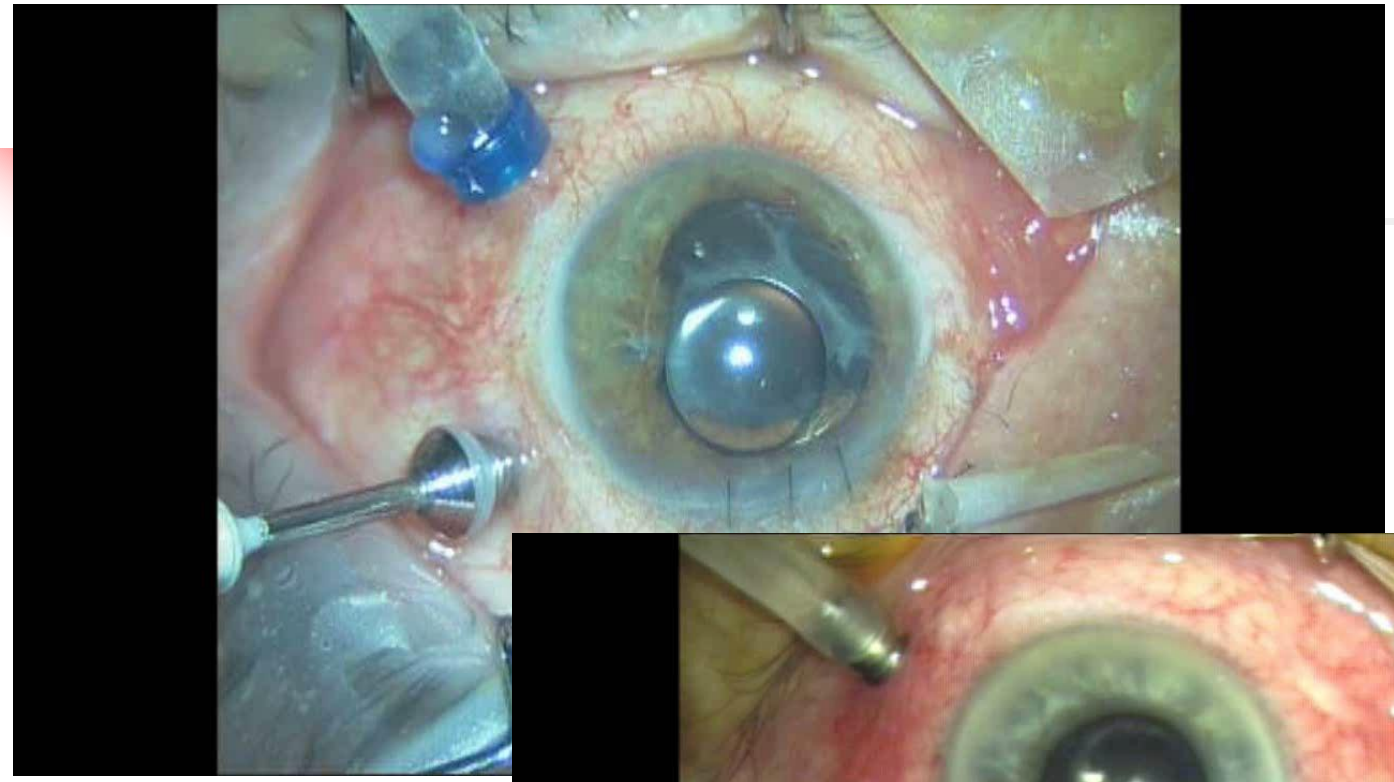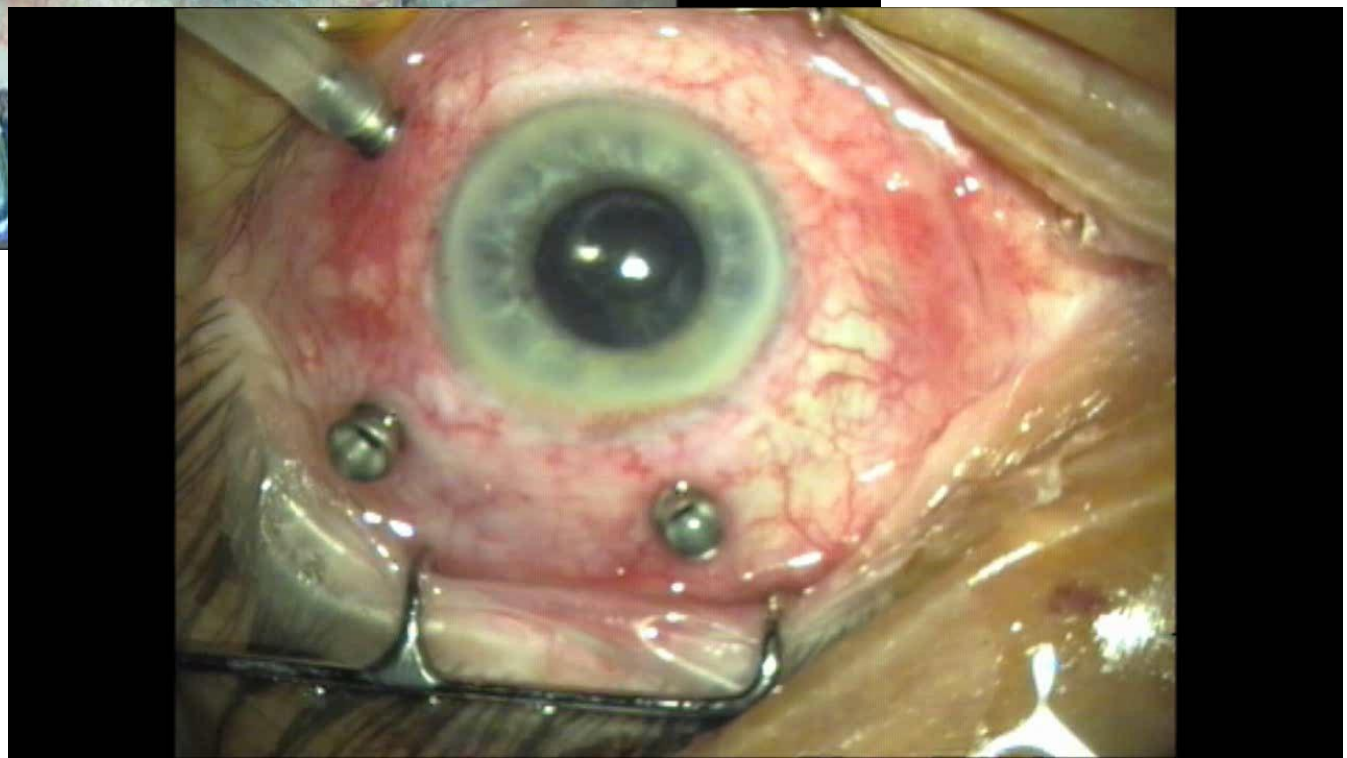
Silikon alınması